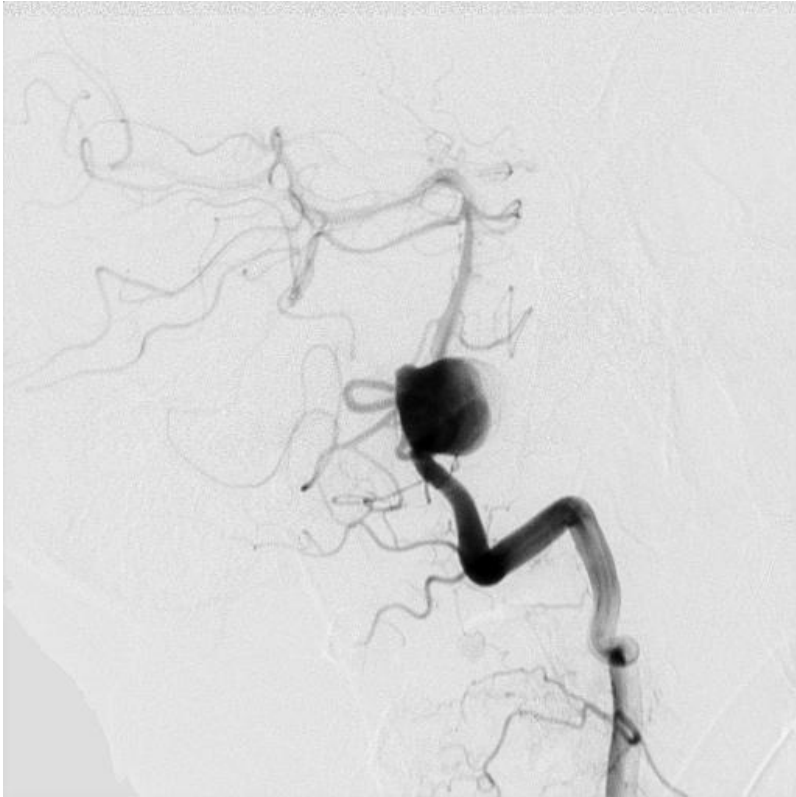

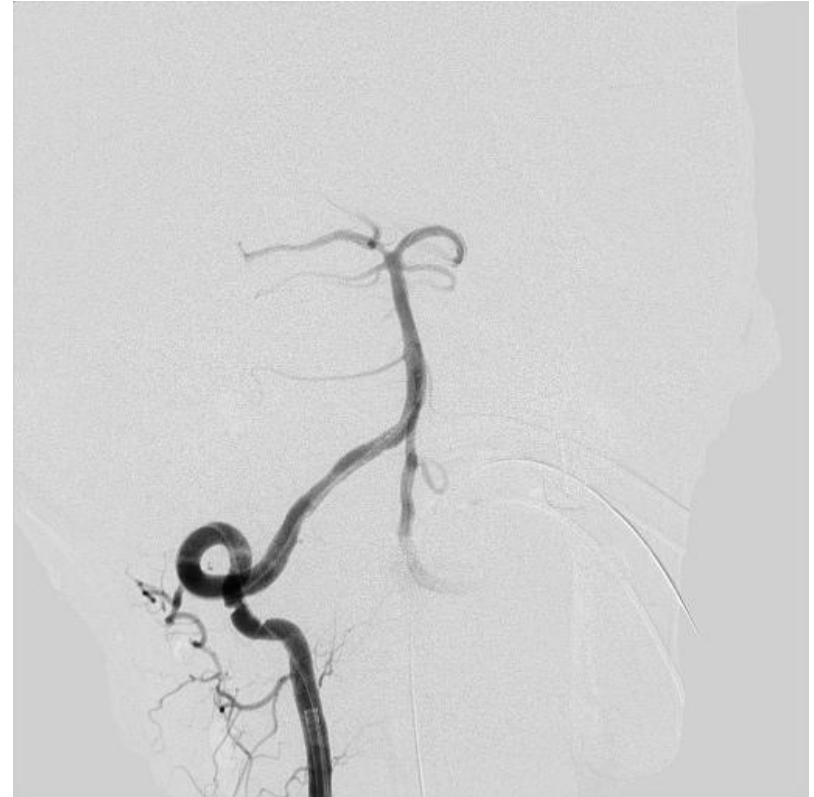


Case #8 **Courtesy of : Dr. Kandyba**
Russian Academy of Medical Sciences
Stent Used: Aneugraft Ø 4x18

- **Case Description: Large Aneurysm of the right Vertebral Artery (V4 in the mouth of PICA)**
 - Patient complained of recurrent headaches and staggers when walking.
 - 07/09/2009, Acute pain in during physical exertion, hypertensive crisis developed, severe headaches, nausea, vomiting.
 - MRI verified subarachnoid hemorrhage.
 - Cerebral angiography revealed a large 18x13x15 dissecting aneurysm of the V4 segment of right vertebral artery aneurysm with wide neck.
 - 17/02/2010, stenting of the right vertebral artery at the neck of the aneurysm with occlusion of the PICA, offset with collateral blood flow from the AICA (Aneugraft 4x18).
 - Postoperative period without complications. Neurological without negative dynamics. Recommendations: Plavix 75 mg / day for 3 months, aspirin 150 mg / day for 6 months.



Pre Intervention



Post Intervention