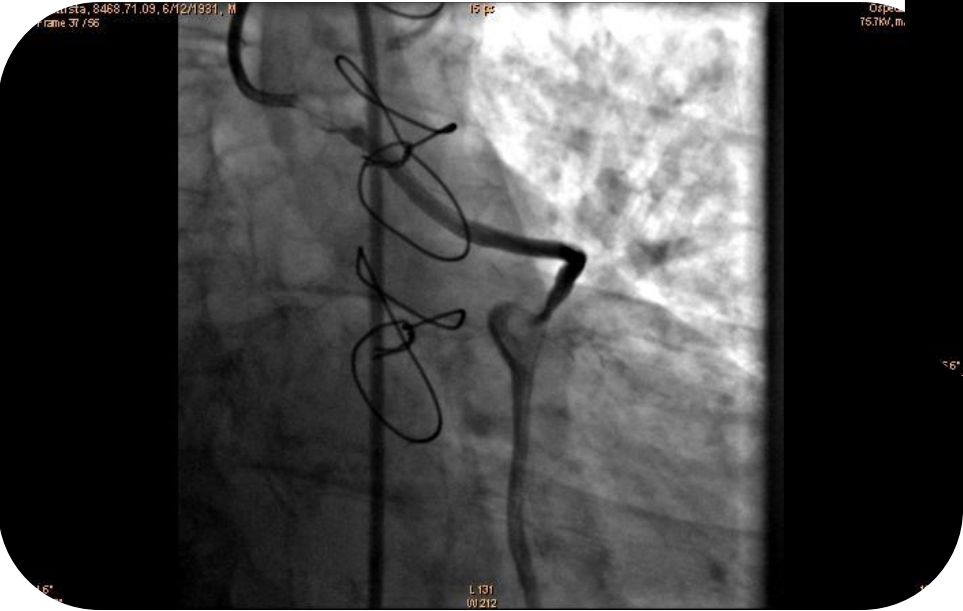


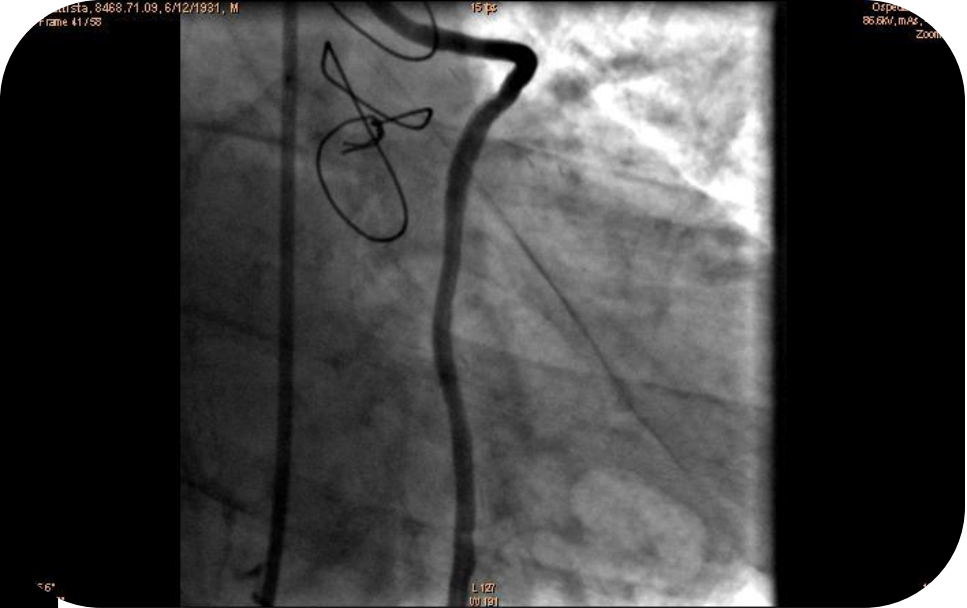
**Courtesy of : Dr. Caccuci**  
**Department of Cardiology, Maggiore Hospital, Italy**  
**Stent Used: Aneugraft Ø3.5X23**

**Case Description:** Aneurysm repair

Aneurism on SVG



Pre Intervention



Post Intervention