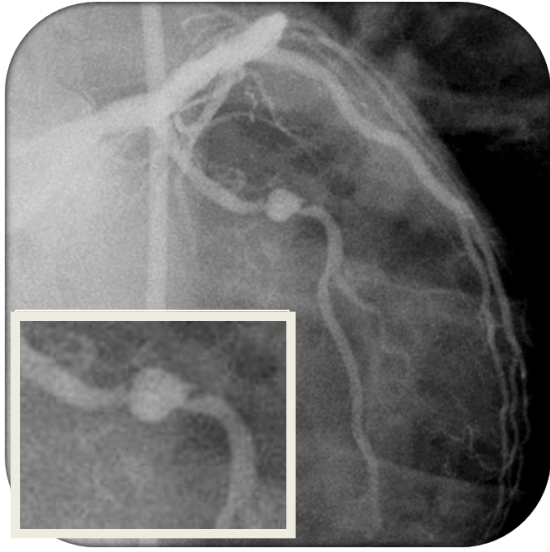


**Courtesy of : Dr. Jorge Gaspar**  
**Instituto Nacional de Cardiología Ignacio Chávez, Mexico City, Mexico**  
**Stent Used: Pericardium Covered Ø 3.0x18mm**

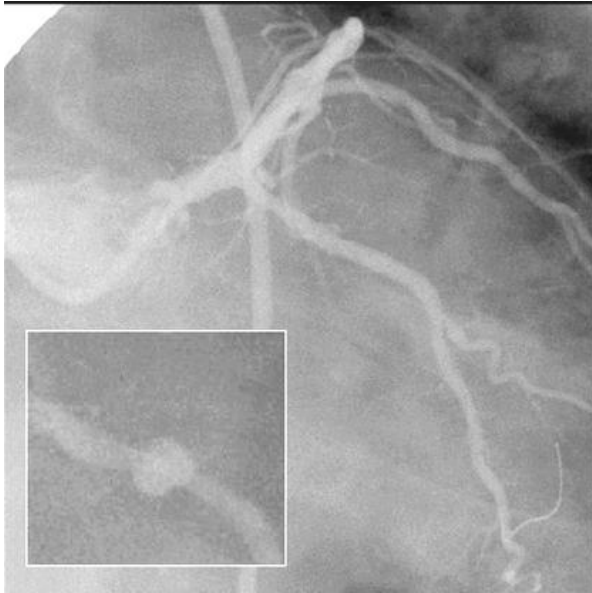
**Case Description:**

- Circumflex artery with 85% stenosis preceded by a saccular (6.5 mm) aneurysm. Predilated with a 3.0x20mm balloon. 3.0x18mm PCS GFX2 stents was placed .
- 8 months follow up: Patient continued to be asymptomatic with no change on angiography.

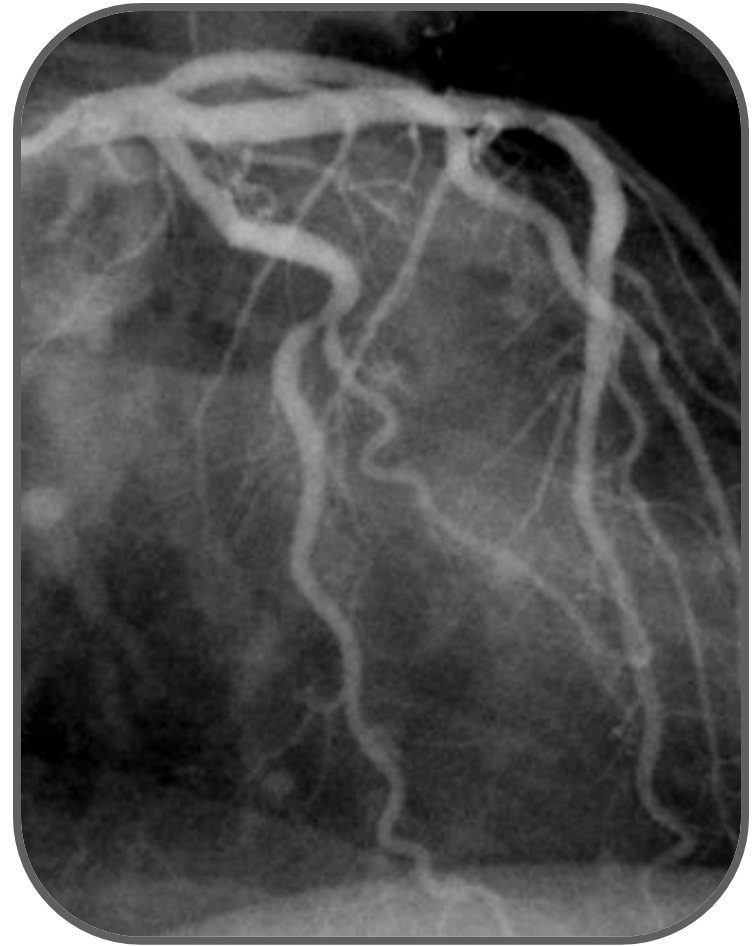*Published: Gaspar J, Vonderwalde C, Almagor Y et al. Stent-graft (SG) with bovine pericardium (BP): acute results in porcine coronary arteries. Am J Cardiol 1998; 82:5S-6S.*



Pre Intervention



Post Intervention



8 months follow up