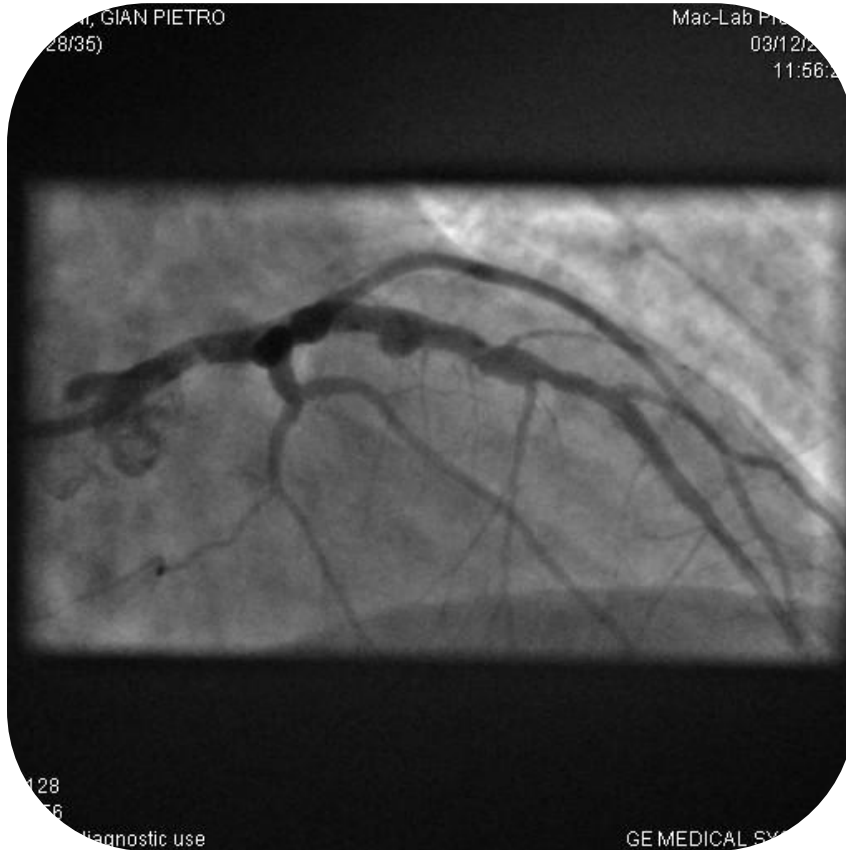

**Courtesy of : Dr. Tondi**  
**Department of Cardiology, Modena Hospital**  
**Stent Used: Over and Under Ø3.5X23**

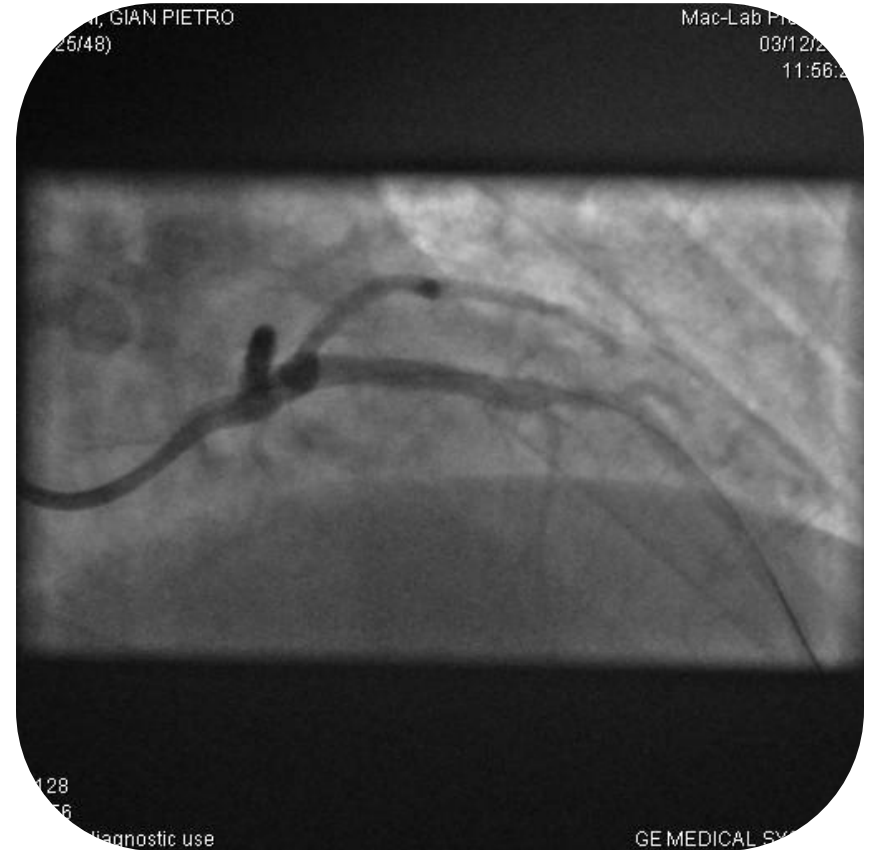
**Case Description:** Aneurism occlusion

- Patient was admitted for Aneurism on LAD. Aneurism on RCA found.
- Procedure to occlude RCA to be done one week later because a branch was occluded on the LAD

# Treatment of the LAD

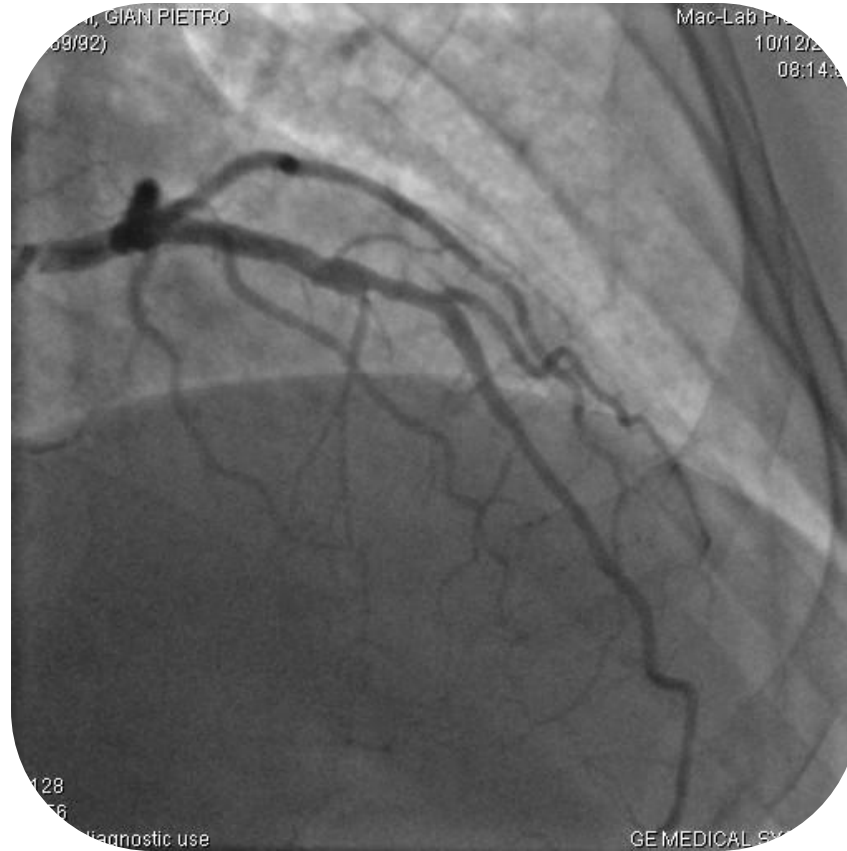


Pre Intervention

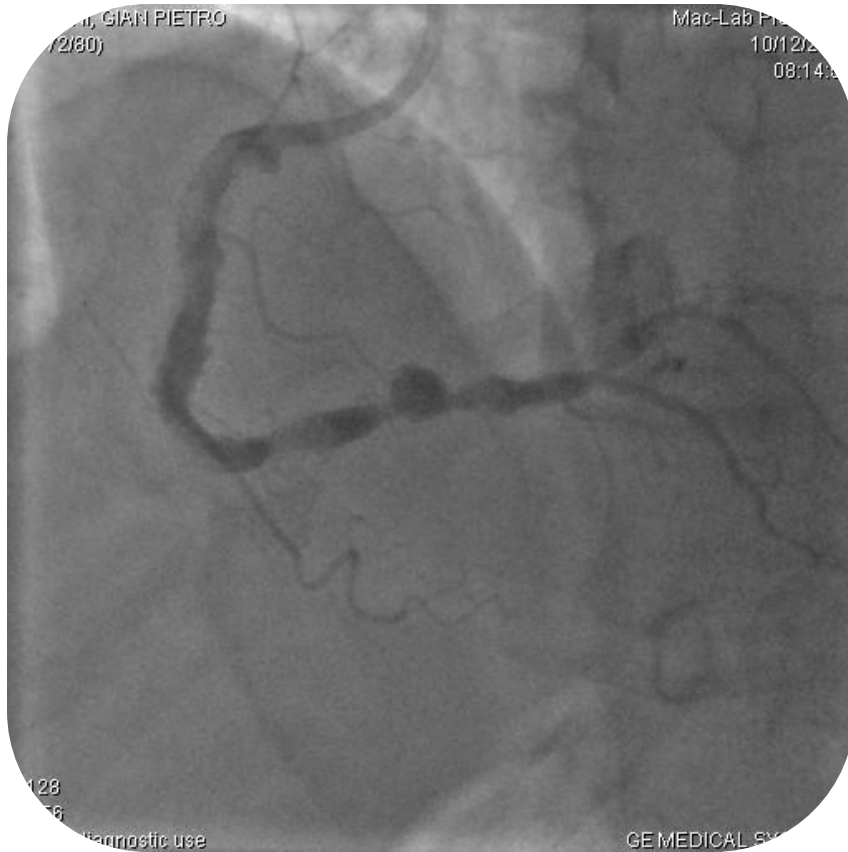


Post Intervention

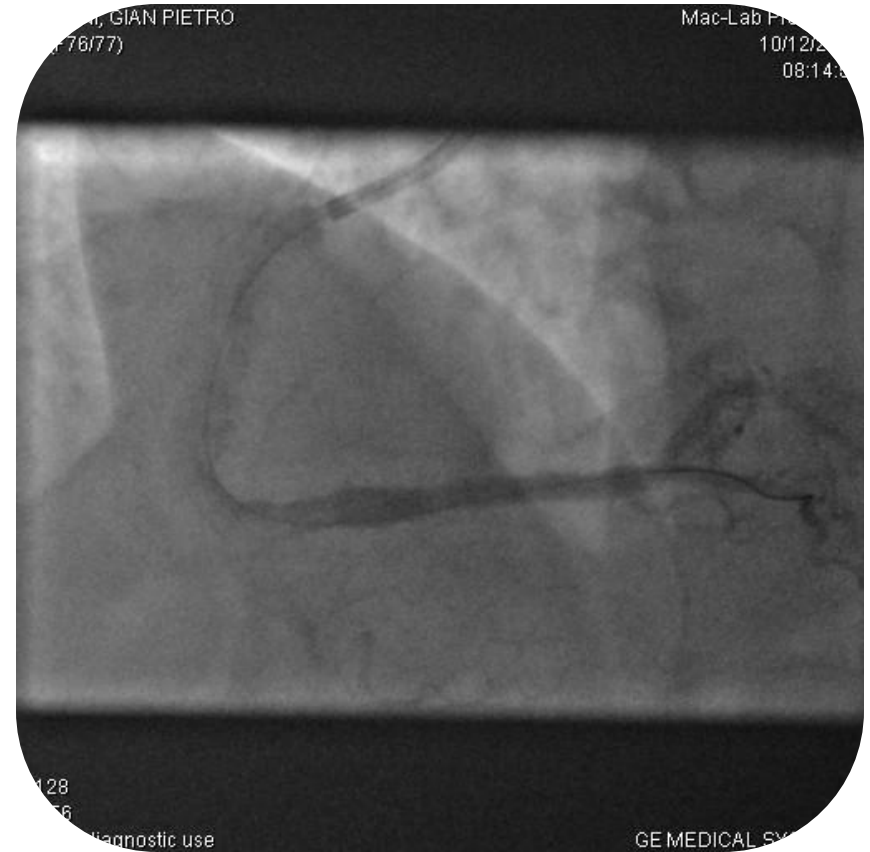
# One week follow up (LAD)



# Treatment of the RCA



Pre Intervention



Post Intervention