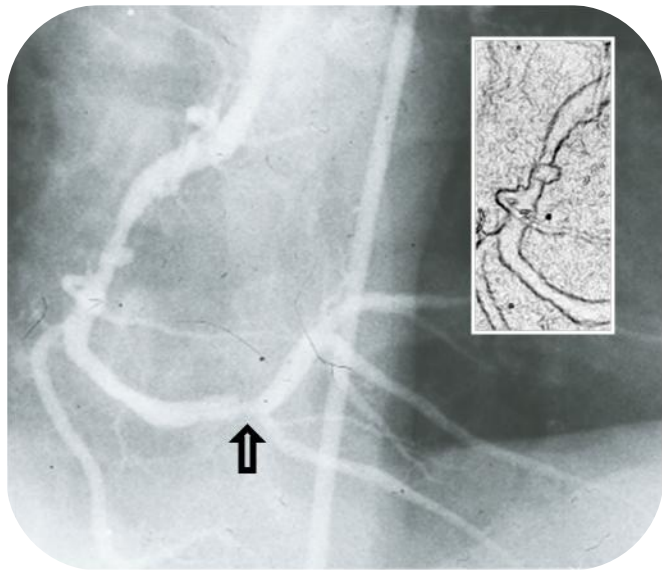


Courtesy of : Dr. Jorge Gaspar
Instituto Nacional de Cardiología Ignacio Chávez, Mexico City, Mexico
Stent Used: Pericardium Covered Ø 4 x 18

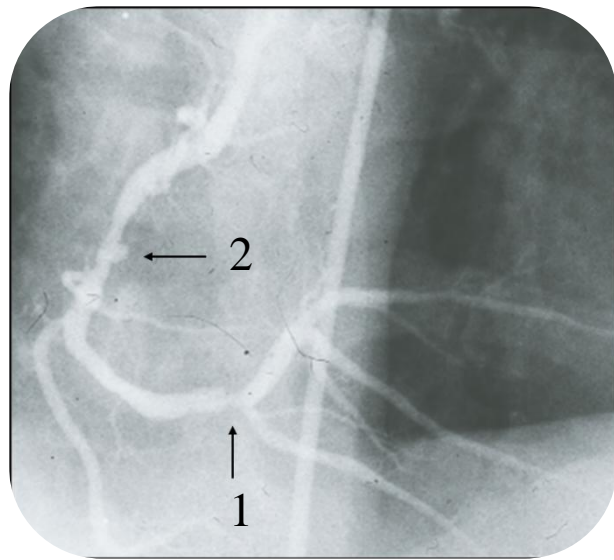
Case Description:

➤ RCA in shallow left anterior oblique. A globular aneurysm of the mid RCA as well as a 85% slit-lesion of the distal RCA

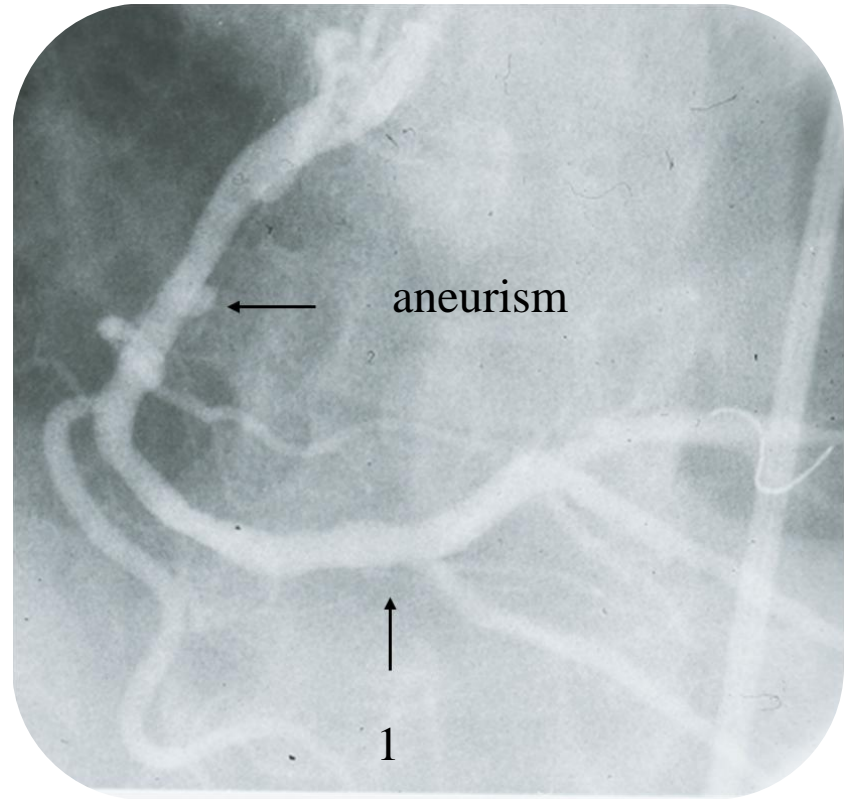
Published: Gaspar J, Vonderwalde C, Almagor Y et al. Stent-graft (SG) with bovine pericardium (BP): acute results in porcine coronary arteries. Am J Cardiol 1998; 82:5S-6S.



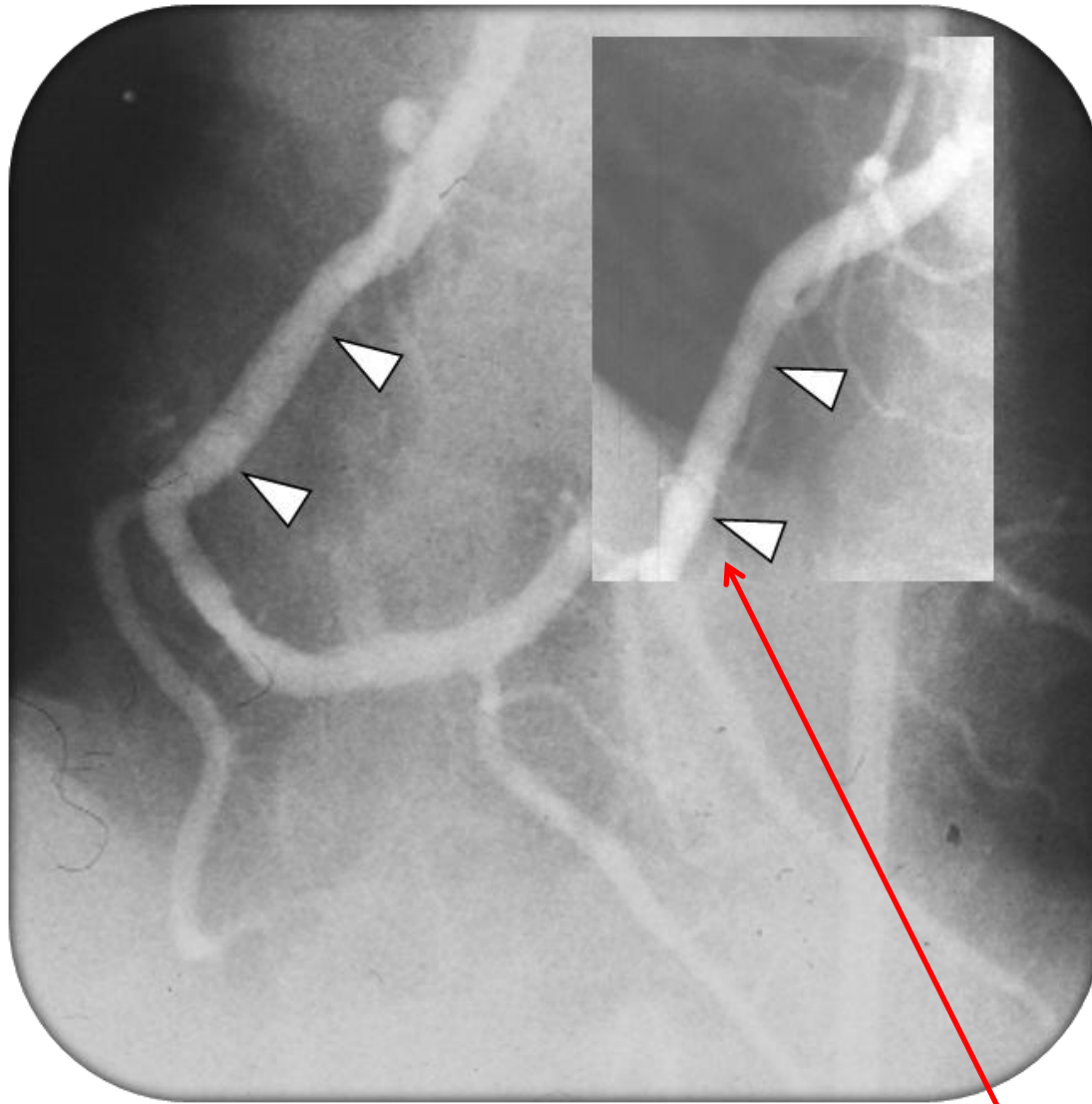
Pre Intervention



RCA with distal lesion (1)
and aneurism. (2)



Stent on RCA distal lesion (1)



Post Intervention

Inset: Follow up at six month
revealed no significant changes at
the stent.