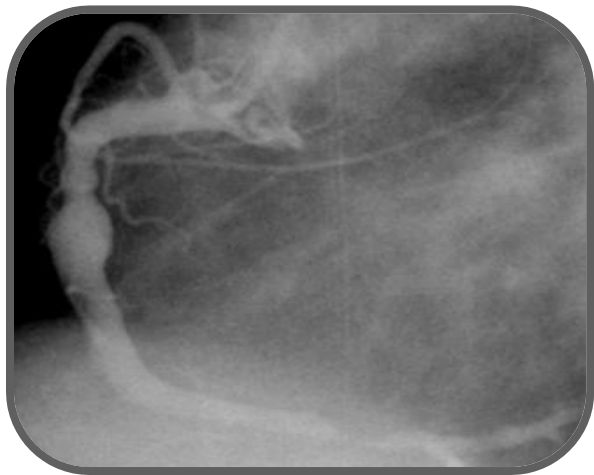


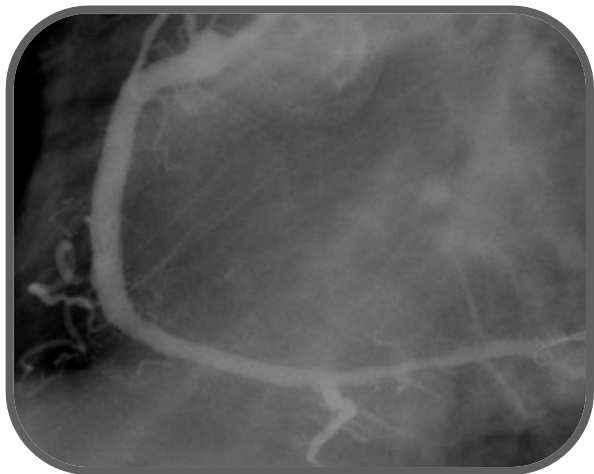Courtesy of : Dr. Ramon Villavicencio
Department of Interventional Cardiology of the Instituto
Nacional de Cardiologia in Mexico City
Stent Used: Over and Under PCS 4.5 x 23

Case Description: RCA aneurysm in the mid segment with a second distal lesion.

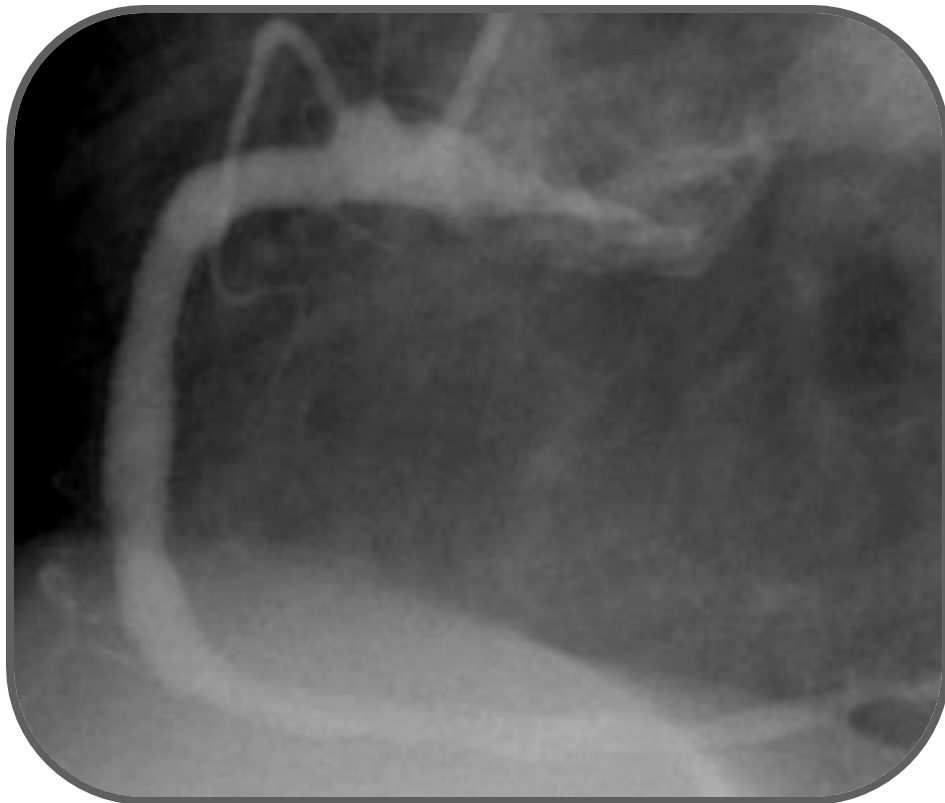
- 59 year old male patient with an aneurysmatic lesion on the mid segment of the RCA and a distal lesion. Distal Lesion treated with a regular stent.
- Aneurysmatic lesion treated with a 4.5 X 23 mm Pericardium covered stent
- 8 months follow up shows excellent result in both lesions



Pre Intervention



Post Intervention



8 month follow up