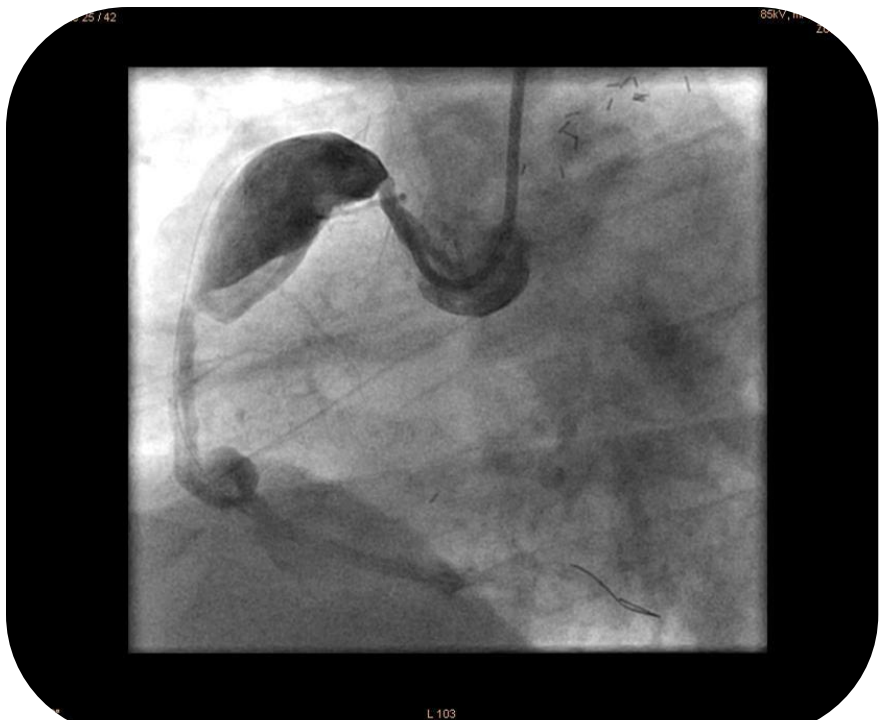


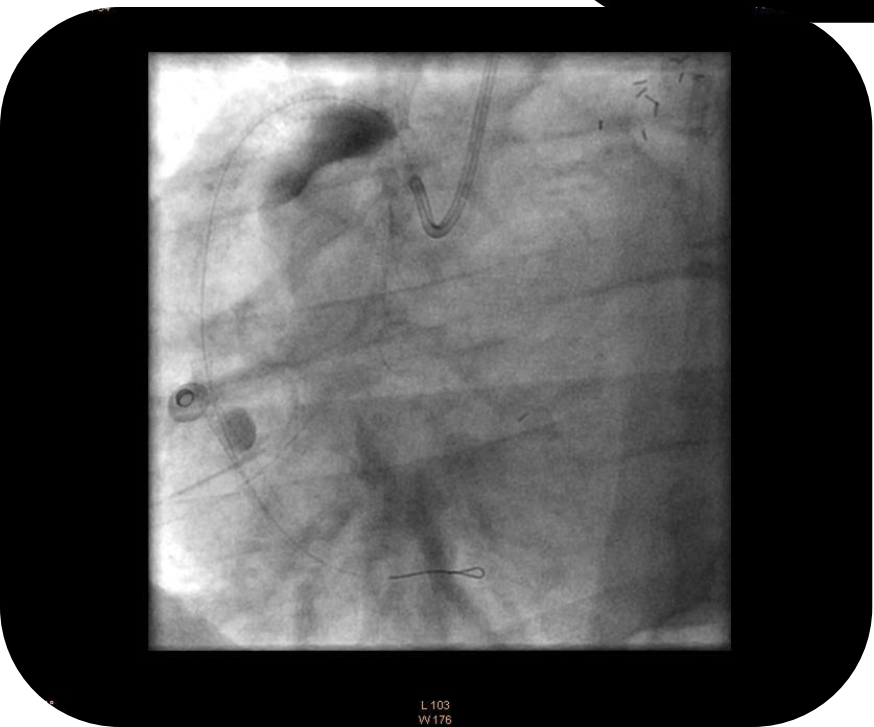**Courtesy of : Dr. S. Hoseyni Guyomi**  
**UMC Utrecht, Netherlands**  
**Date: July 24, 2009**

**Case Description: RCA aneurysm with 2 aneurysm**

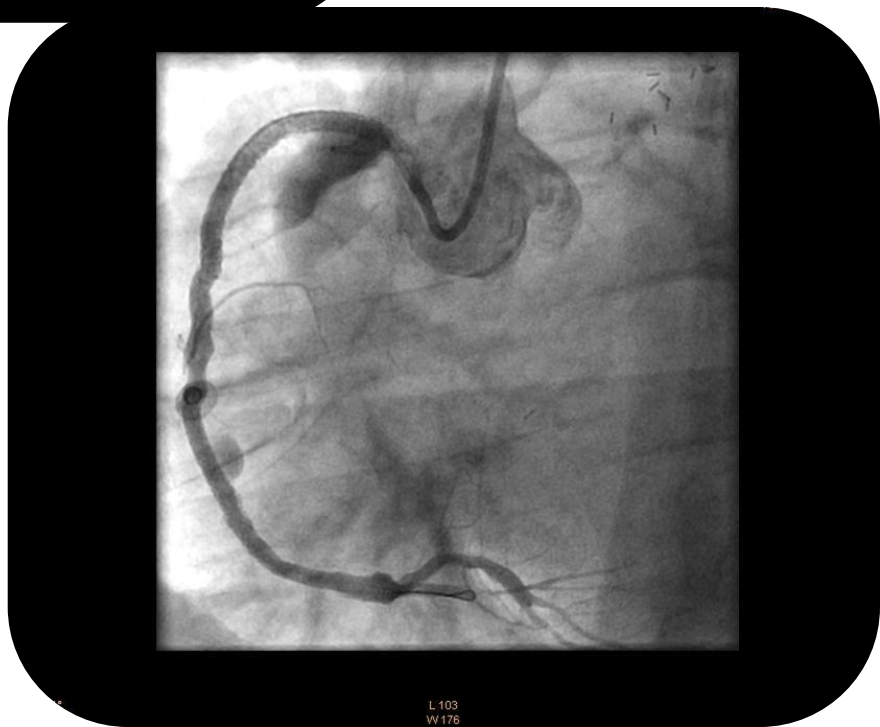- Patient with an huge aneurysm in the RCA and a distal aneurysm in the RCA.
- Aneurysmatic lesion treated with a multiple Pericardium covered stents. Distal aneurysm treated with a Pericardium stent as well
- Clinical follow up, patient continues to do well.



L 103  
W 160



L 103  
W 176



L 103  
W 176