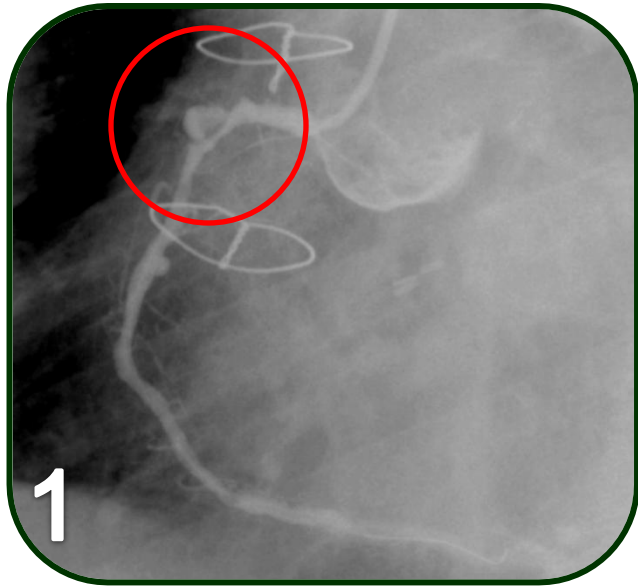


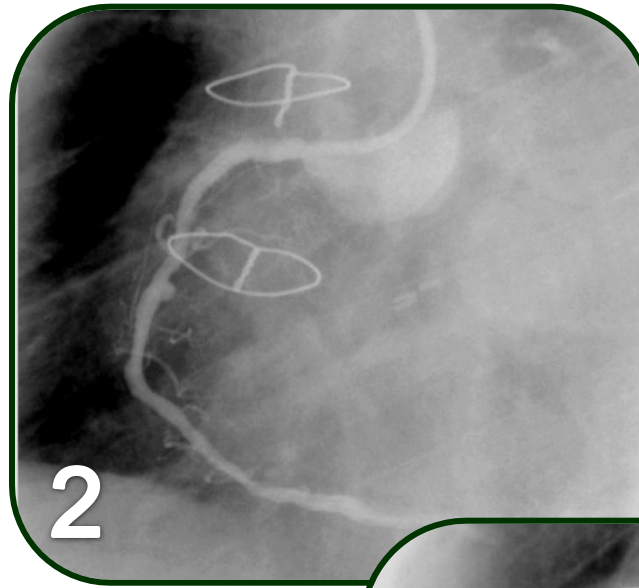
Courtesy of : Dr. Michael Pitt
Department of Cardiology, Heart of England NHS Foundation
Trust, UK
Stent Used: Over and Under PCS Ø3.5X18

Case Description: Aneurysm repair

- Aneurism on RCA
- Re-visit to the lab was scheduled following diagnosis of aneurysm which had changed its shape, therefore needed to be treated. Prev MI + Left vessel CABG
- A proximal O&U stent deployed in the aneurismatioc site, a cypher stent was deployed distally because of a question of distal edge tear from the O and U stent.



Cypher was deployed tandem to Over and Under (distal portion)



Following deployment of Over and Under PSC Ø3.5X18 – Aneurism is excluded

