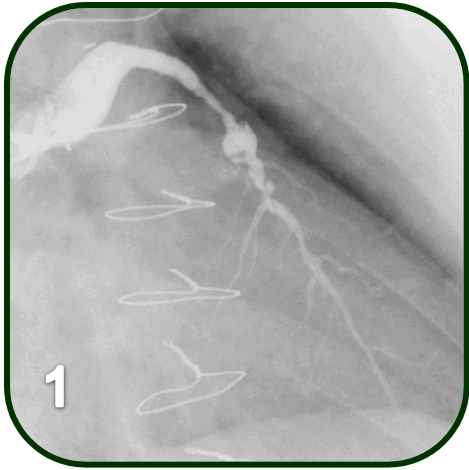


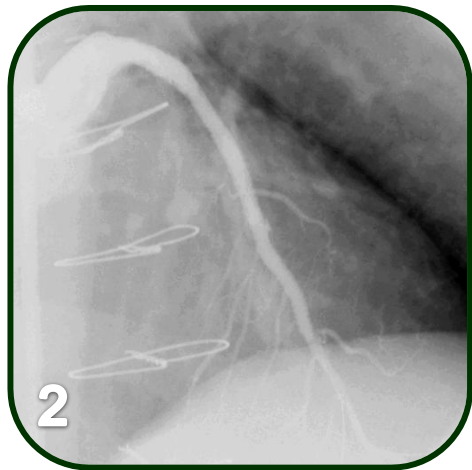
**Courtesy of : Dr. Jorge Gaspar**  
**Instituto Nacional de Cardiología Ignacio Chávez, Mexico City, Mexico**

**Case Description: SVG and Aneurysm repair**

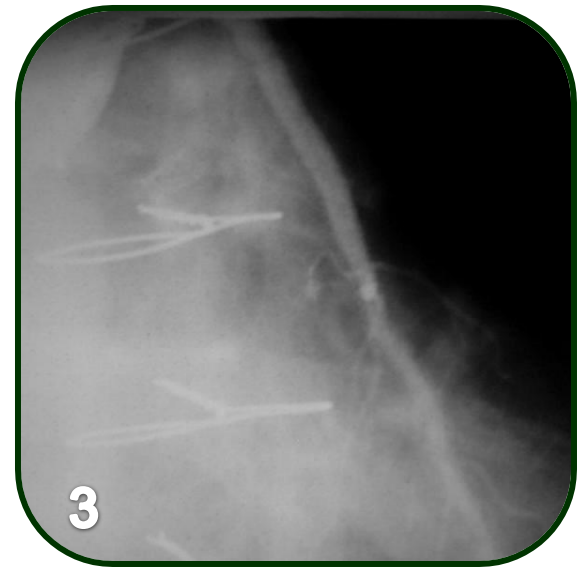
- 13 year-old degenerated SVG to LAD
- An aneurysm containing a thrombus
- Patient arrived the day before with an AMI and the graft totally occluded



Pre Intervention



Post Intervention



8 months follow-up