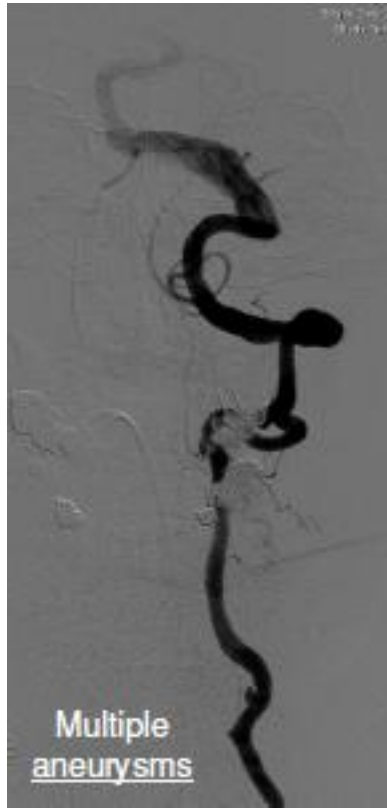


Courtesy of : Dr. Shimon Maimon
Tel Aviv Sourasky Medical Center
Stent Used: Aneugraft Ø 4x13

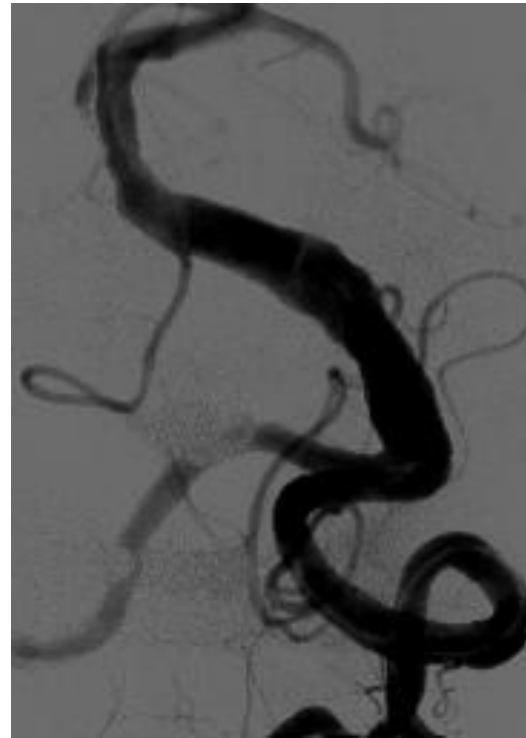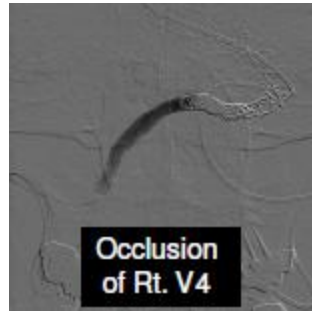
Case Description: Dissecting Basilar Artery Aneurysm

- 3.5 years ago a mild V.B. event. Mild ectasia and small dissection in the proximal Basilar artery
 - Treated with Heparin then Aspirin. Stable for 2 years.
 - At follow up CTA, big partially thrombosed aneurysm developed.
- First treatment 2 overlapped LEO stents
- Second treatment additional 2 overlapped LEO stents
- 2 Week Clinical Improvement
 - Off ventilation
 - Started moving left side
 - Fully Alert and Started Eating
 - CTA – Second lumen closed

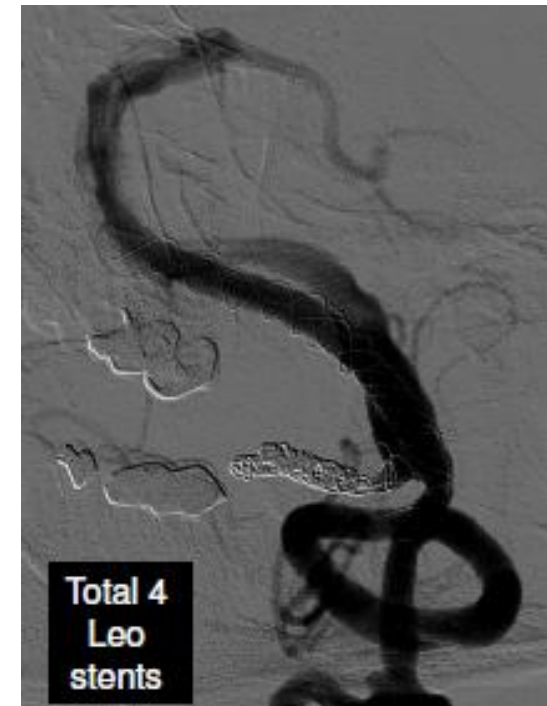
Pre PCS



Pre Intervention

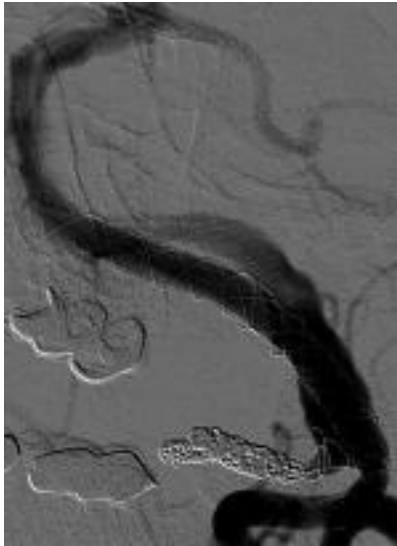


Post 2 Leo Stents

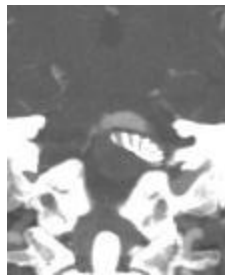

Post 4 Leo Stents

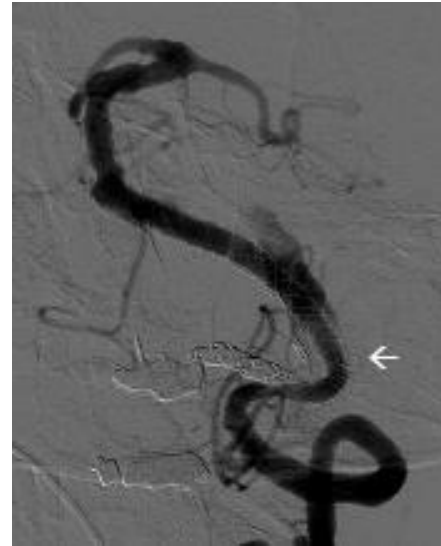Post PCS



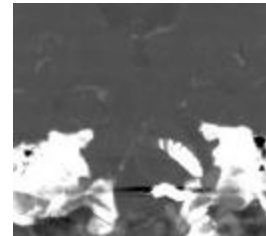
Last treatment of 4 Leo stents



Pre PCS



Post 4x13 PCS stent
in the inflow zone



Post PCS