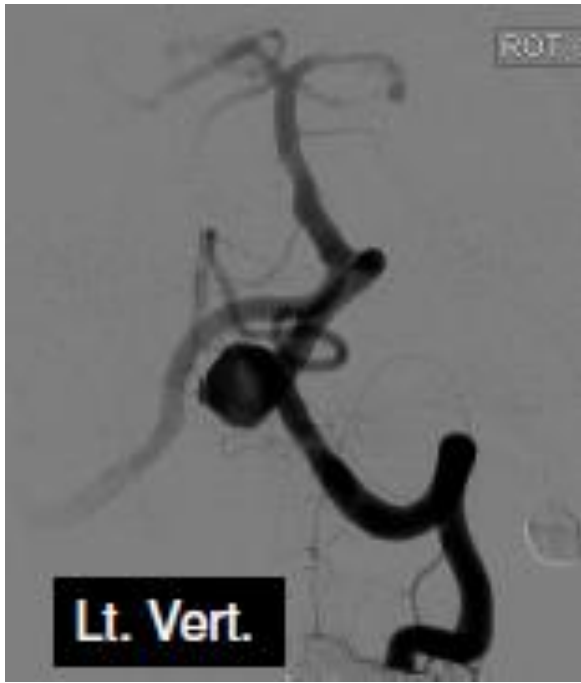

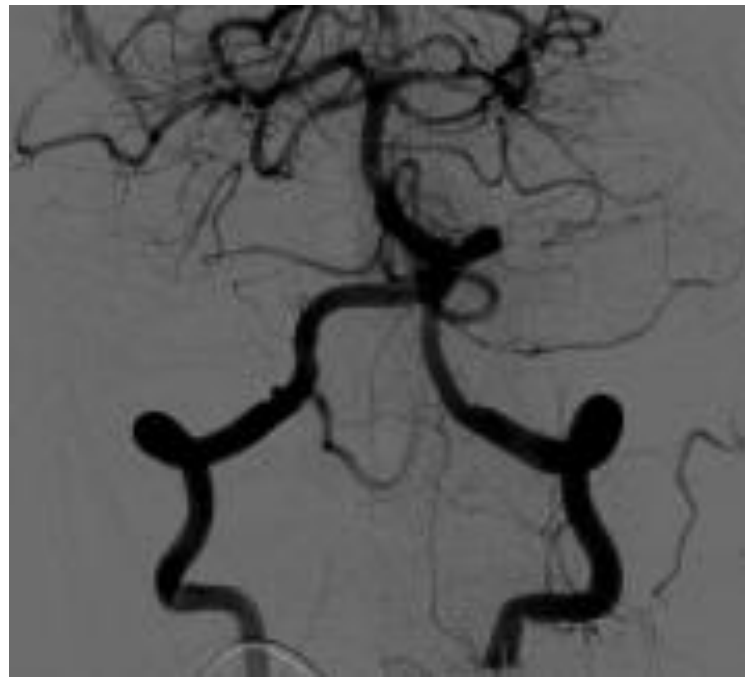
**Courtesy of : Dr. Shimon Maimon
Tel Aviv Sourasky Medical Center
Stent Used: Aneugraft**

Case Description: Large Wide Neck Aneurysm

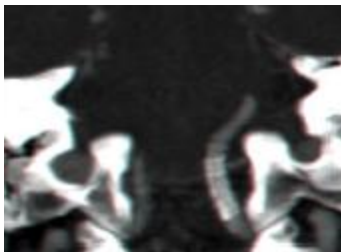
- Wide neck aneurysm proximal to left PICA
- 3 Months CTA showed complete occlusion of the aneurysm



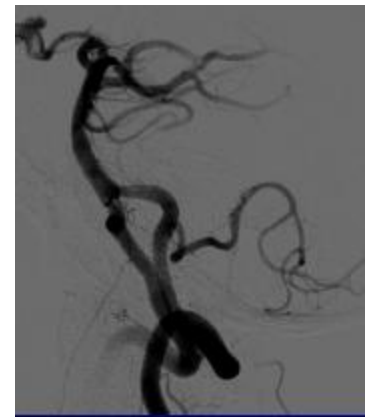
Pre Intervention



Post Intervention



CTA at 3 months



Post Intervention