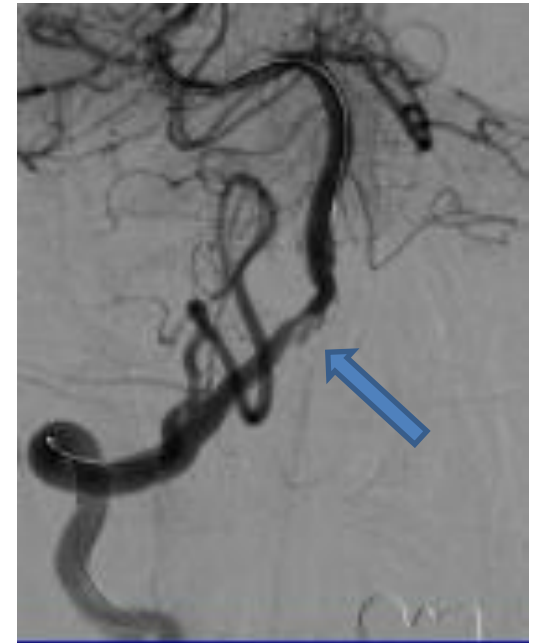
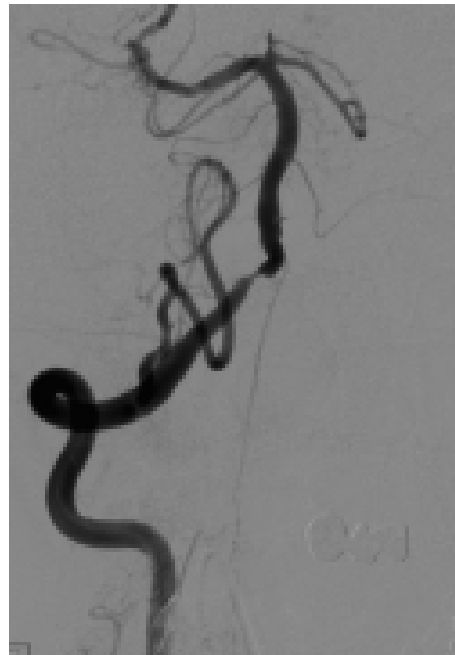
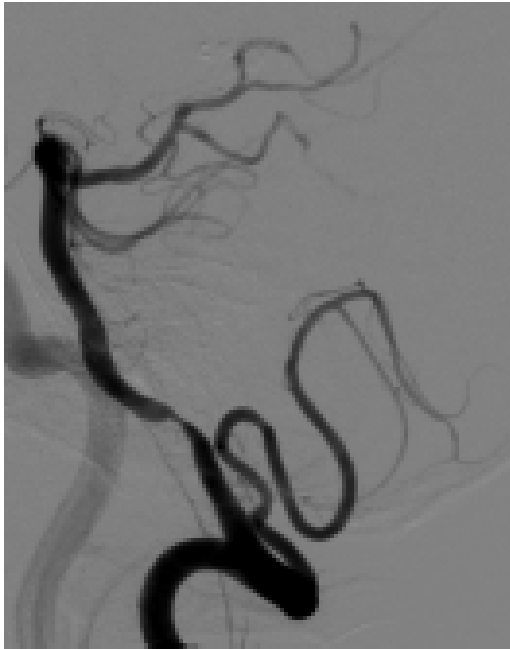**Courtesy of : Dr. Shimon Maimon
Tel Aviv Sourasky Medical Center
Stent Used: Aneugraft Ø 3.5x18**

Case Description: Right Vertebral Artery Dissection

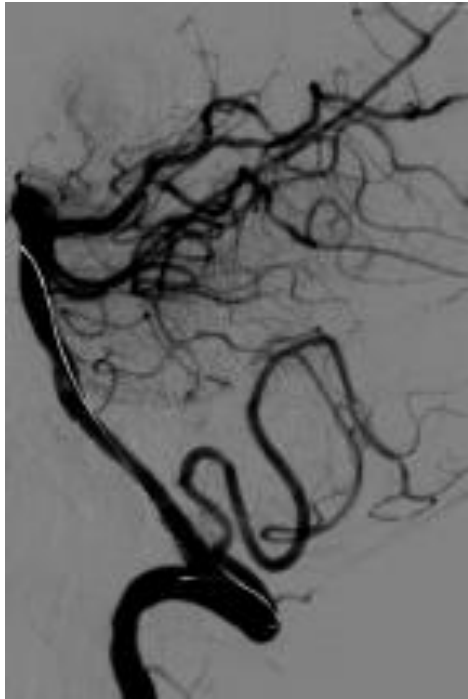
- Left Vertebral artery occlusion and severe stenosis in the Right Vertebral artery
 - Small left P1
 - PTA 3x10mm balloon in right V.B. junction causes dissection and/or leakage
- Patient discharged home 2 days following procedure
- 3 Months CTA showed complete occlusion of the aneurysm

Pre PCS

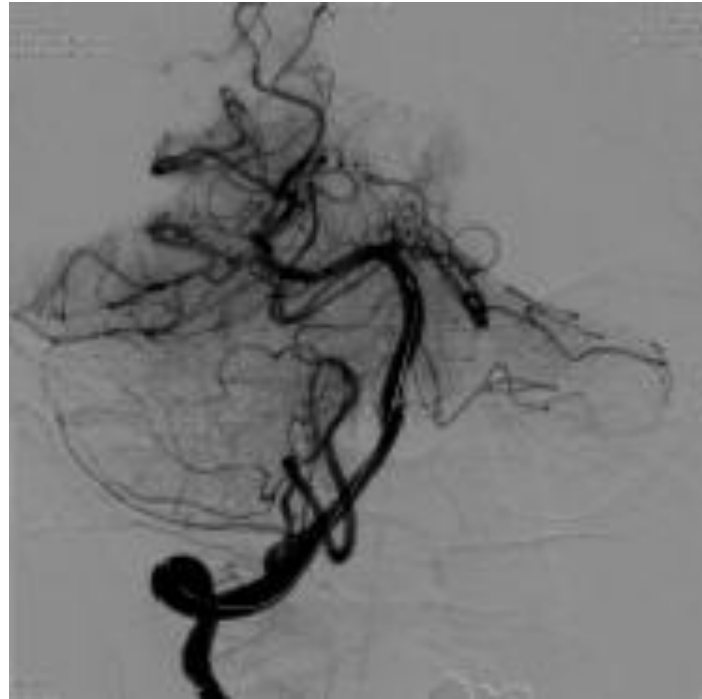


PTA 3x10mm balloon in right V.B.
junction causes dissection and/or
leakage

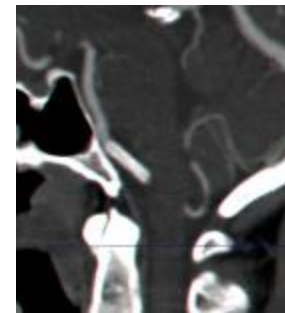
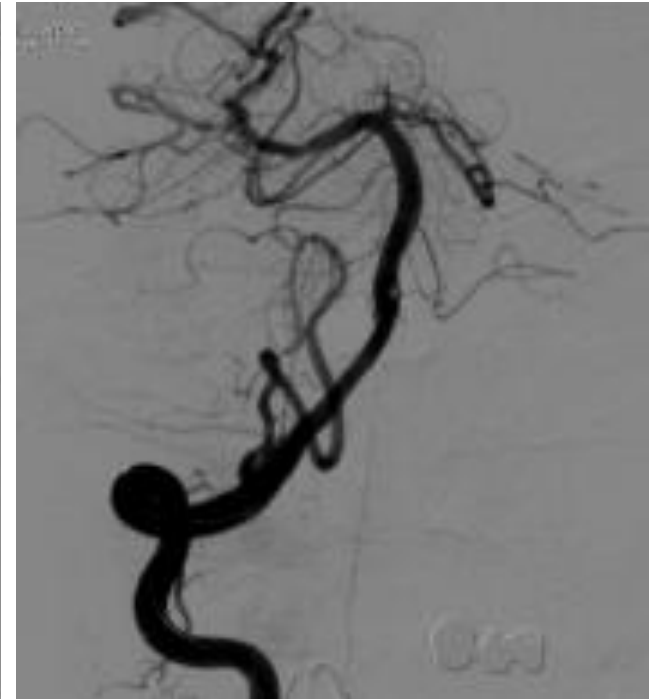Post PCS



ASA open



PCS 3.5 x 18 in Rt. V.B.
Junction



4 months CTA